



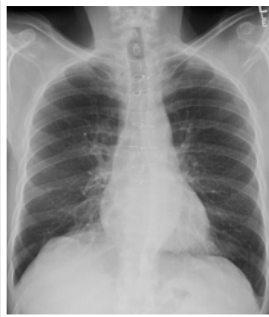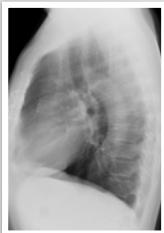
## The post-op chest

Cardiac

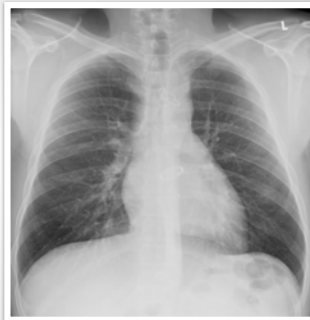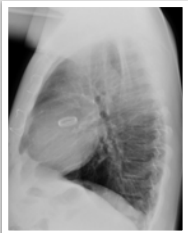
### What will I gain from this video?

At the end of this video, you will know how to recognize the radiological features related to cardiac surgery.

### Cardiac bypass



**Cardiac valvular  
replacement**



---

---

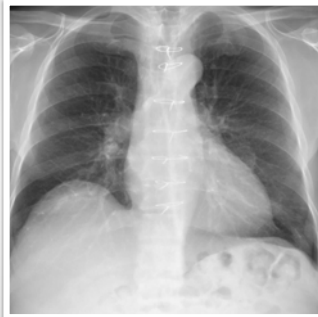
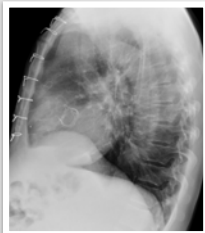---

---

---

---

**Cardiac valvular  
replacement**



---

---

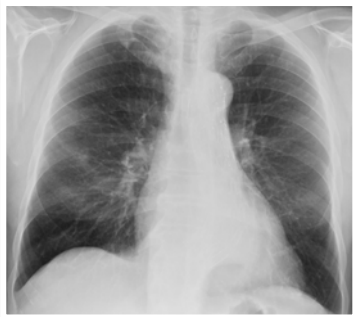
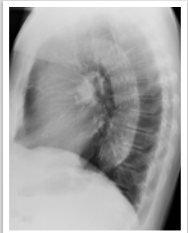---

---

---

---

**Cardiac  
EVAR**



---

---

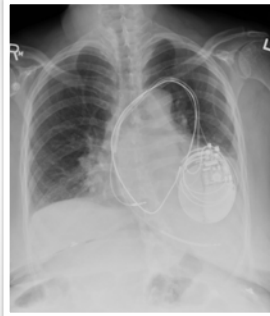
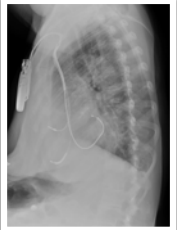---

---

---

---

### Cardiac pacemaker



---

---

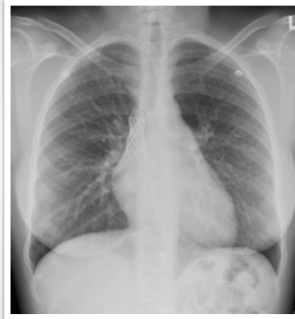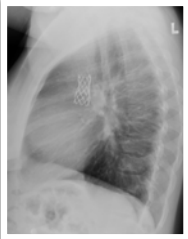---

---

---

---

### SCV stent



---

---

---

---

---

---

Always compare to previous X-rays to identify complications.

Understand what type of surgery was performed.

Appearance will depend on type of surgery.

Early and late postoperative complications can occur.

---

---

---

---

---

---